

Management of Acute Respiratory Failure Secondary to Seasonal Influenza

César Cinesi-Gómez*

Faculty of Medicine, San Antonio Catholic University (UCAM), Spain

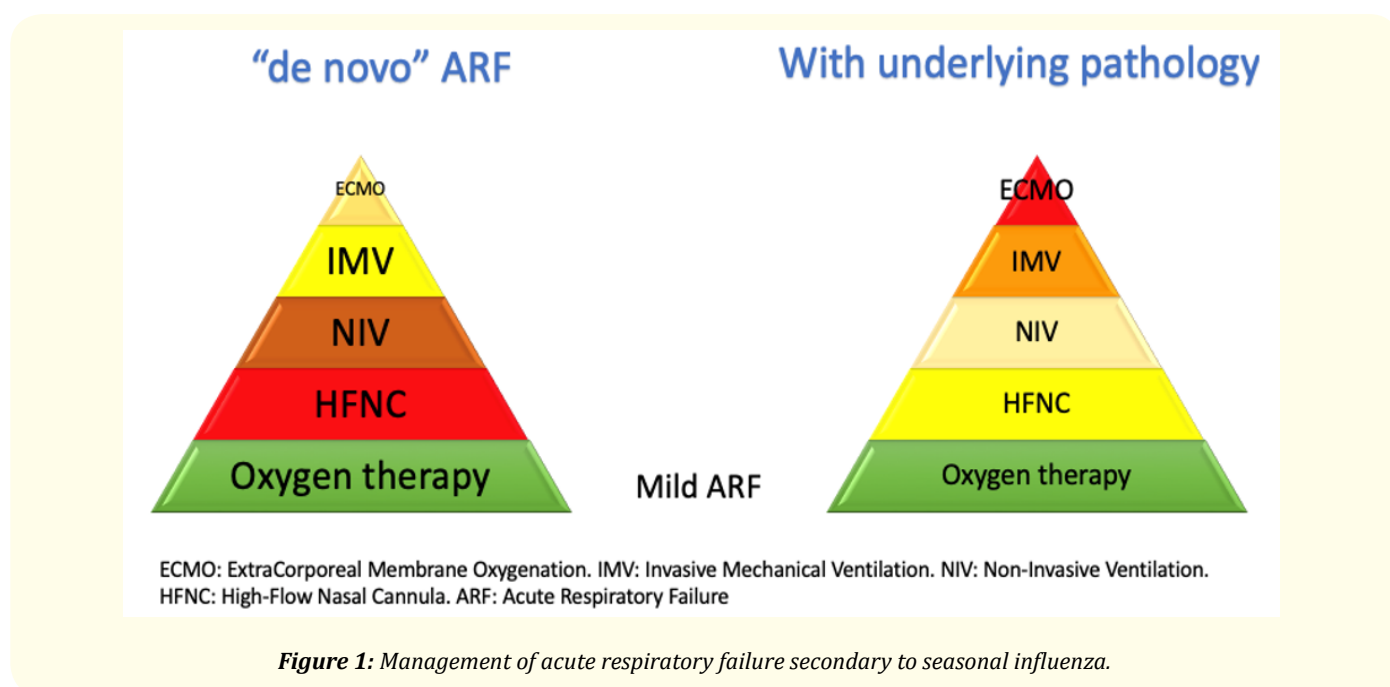
*Corresponding Author: César Cinesi-Gómez, Faculty of Medicine, San Antonio Catholic University (UCAM), Spain.

Received: February 18, 2019; Published: February 21, 2019

The seasonal epidemic of influenza A and B infection is associated with morbidity and mortality annually [1]. In the epidemics of the years 2010 - 2018 were calculated from 4.3 to 23 million medical consultations, 140,000 to 960,000 hospital admissions and between 12,000 and 79,000 annual deaths in the United States [2]. Acute respiratory failure (ARF) is the most frequent cause of mortality in patients with influenza. It is essential to apply a therapeutic strategy for ARF secondary to infection with the influenza virus. In general, the therapeutic pyramid proposed by Scala and Heunks [3] can be used.

Conventional oxygen therapy is based on the administration of oxygen at different concentrations and is the base of the pyramid. It should only be used in case of mild ARF. If the patient presents severe ARF, scalar should be considered in the therapeutic pyramid. The next step is high-flow nasal cannula (HFNC), new therapy every day more and more. It is based on the use of air enriched with oxygen at high flows (around 60 bpm) through a nasal cannula. This administered air must be hot and humidified at 100%. The advantages with respect to conventional oxygen is a constant and high contribution of FiO_2 , a reduction of dead space and the generation of a positive pressure, which entails a redistribution of intra-alveolar fluid and alveolar recruitment. The next step is non-invasive ventilation (NIV). The main characteristic of NIV is its use with the patient in spontaneous ventilation, so sedation is zero or low [4]. The penultimate step is invasive mechanical ventilation (IMV). In this case, controlled and precise ventilation of a device that protects the airway is usually used [3]. The last step is the extracorporeal oxygenation membrane (ECMO). ECMO is a form of extracorporeal life support that can provide complete (or partial) support of the heart and lungs. It consists in introducing a specialized cannula in a large vessel connecting to a membrane that oxygenates the blood and removes carbon dioxide and a blood pump that drives the blood flow of the circuit [5].

From the therapeutic arsenal described, in the specific case of ARF associated with the influenza virus, there are two fundamental considerations (Figure 1). In all cases of mild respiratory failure, the use of conventional oxygen therapy through nasal glasses is the choice. In case of severe respiratory failure, the therapeutic option will depend on the patient's underlying pathologies, mainly chronic respiratory diseases and/or the association with heart failure. Therefore, we will have two groups of patients: with underlying pathology or without ("de novo") [6]. The therapeutic options would be the following:



1. Patients with underlying pathology:
 - HFNC: Main resource in case of hypoxemic respiratory failure in patients with heart failure without marked respiratory work [7].
 - NIV: Indicated in patients with exacerbation of COPD and hypercapnic respiratory failure [4].
 - IMV: Second line technique. Its main indication will be in patients with failure of NIV.
 - ECMO: Will only be used in very selected cases [8].
2. Patients with “*de novo* respiratory failure”:
 - HFNC: It presents a high risk of failure. Its indication would be at a very early stage. It requires close monitoring, so it should be performed in an intensive care unit [9]. It should not be used in case of $pO_2/FiO_2 < 150$.
 - NIV: It also has a high failure rate. It requires close monitoring, so it should be performed in an intensive care unit [10]. It should not be used in case of $pO_2/FiO_2 < 150$.
 - IMV: If indicated, it should not be delayed. It would be the most used technique, although in very specialized units in NIV, it is being displaced by the NIV itself.
 - ECMO: Would be indicated in patients with severe failure ($pO_2/FiO_2 < 100$) with poor response to IMV [5,8].

Bibliography

1. Uyeki TM., *et al.* “Clinical Practice Guidelines by the Infectious Diseases Society of America: 2018 Update on Diagnosis, Treatment, Chemoprophylaxis, and Institutional Outbreak Management of Seasonal Influenza”. *Clinical Infectious Diseases* (2018).
2. Estimated Influenza Illnesses, Medical visits, Hospitalizations, and Deaths in the United States - 2017-2018 influenza season. CDC (2018).
3. Scala R and Heunks L. “Highlights in acute respiratory failure”. *European Respiratory Review* 27.147 (2018): 180008.
4. Nava S. “Behind a Mask: Tricks, Pitfalls, and Prejudices for Noninvasive Ventilation”. *Respiratory Care* 58.8 (2013): 1367-1376.
5. Tramm R., *et al.* “Extracorporeal membrane oxygenation for critically ill adults”. *Cochrane Database of Systematic Reviews* 1 (2015): CD010381.
6. Rochweg B., *et al.* “Official ERS/ATS clinical practice guidelines: noninvasive ventilation for acute respiratory failure”. *European Respiratory Journal* 50.2 (2017): 1602426.
7. Carratalá JM., *et al.* “Efectividad y seguridad de la terapia de alto flujo con cánulas nasales en pacientes con insuficiencia cardiaca aguda”. *Emergencias* 30 (2018): 395-399.
8. Sukhal S., *et al.* “Extracorporeal membrane oxygenation in severe influenza infection with respiratory failure: A systematic review and meta-analysis”. *Annals of Cardiac Anaesthesia* 20.1 (2017): 14-21.
9. Brouzet B., *et al.* “High-flow oxygen therapy in acute respiratory failure secondary to influenza virus infection”. *Emergencias* 30.5 (2018): 360.
10. Masclans JR., *et al.* “Early non-invasive ventilation treatment for severe influenza pneumonia”. *Clinical Microbiology and Infection* 19.3 (2013): 249-256.

Volume 8 Issue 3 March 2019

©All rights reserved by César Cinesi-Gómez.